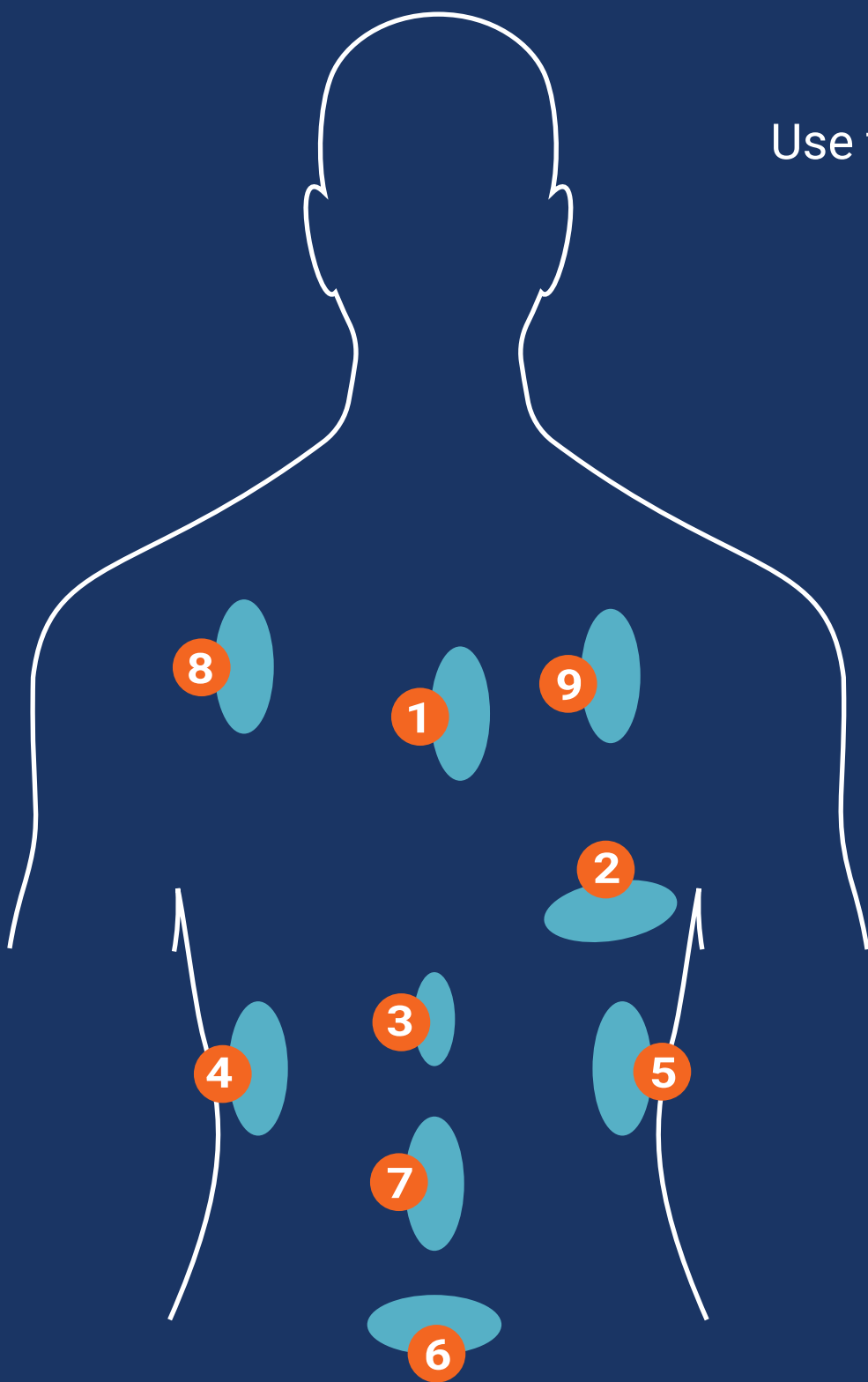


Rush Exam Protocol

Rapid Ultrasound for Shock and Hypotension



Use the mnemonic **HIMAP-"ED"** to remember...

Heart

- 1 Parasternal long cardiac view
- 2 Apical 4-chamber cardiac view

Ivc

- 3 Inferior Vena Cava View

Morison's

- 4 RUQ Morison's view
- 5 LUQ splenorenal view
- 6 Bladder view

Aorta

- 7 Aortic slide views

Pulmonary

- 8 Left Lung zone #1
- 9 Right Lung zone #5

✓ Use a curvilinear array for all views.

✓ Add in a search for **ectopic** pregnancy and **DVT** depending upon clinical circumstances.