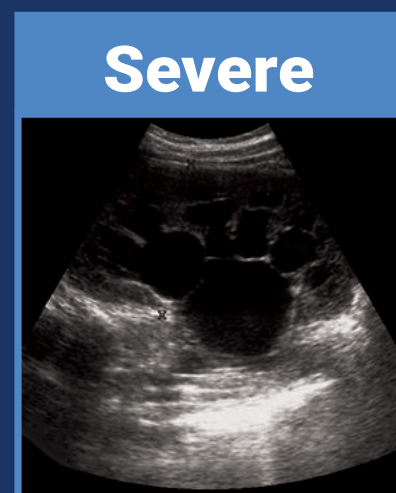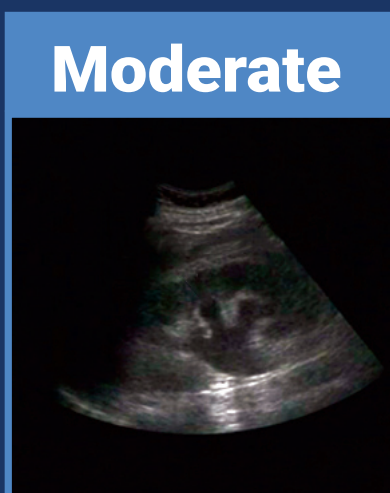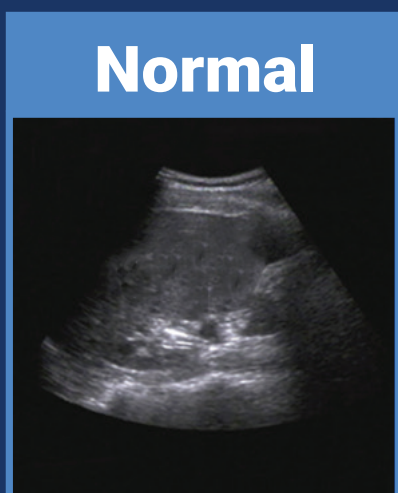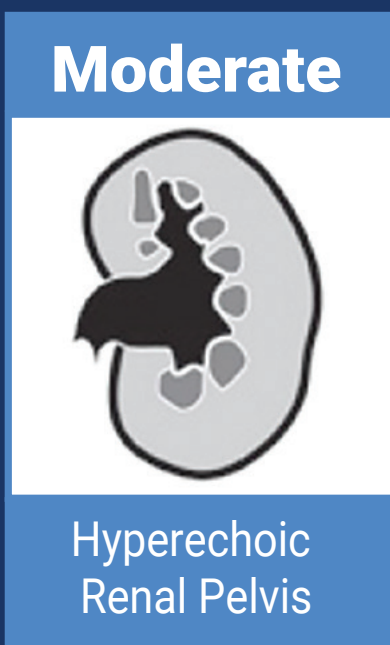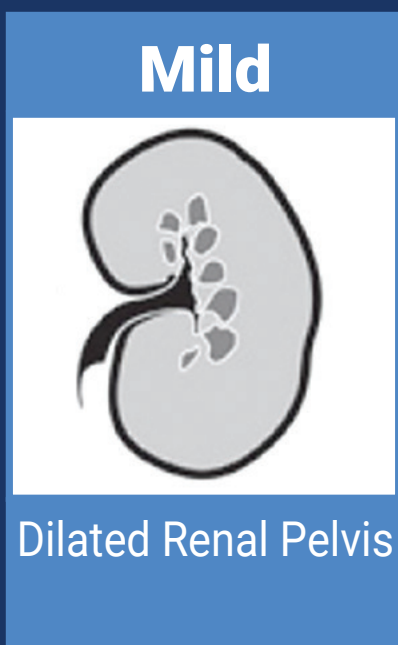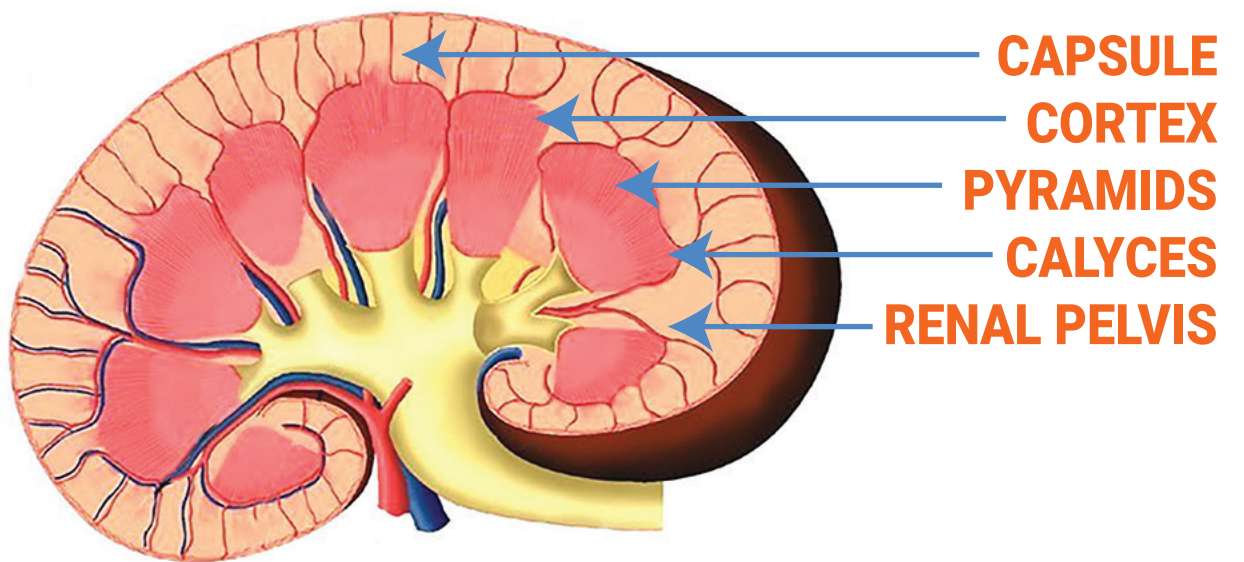


Renal POCUS

Look For Evidence Of Hydronephrosis!

NORMAL ANATOMY →
 The Renal Pelvis is hyperechoic on ultrasound.



↑
Hydronephrosis