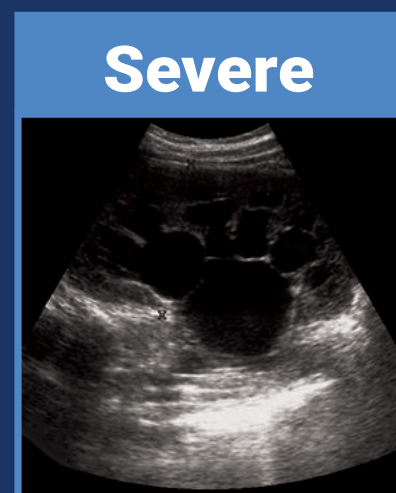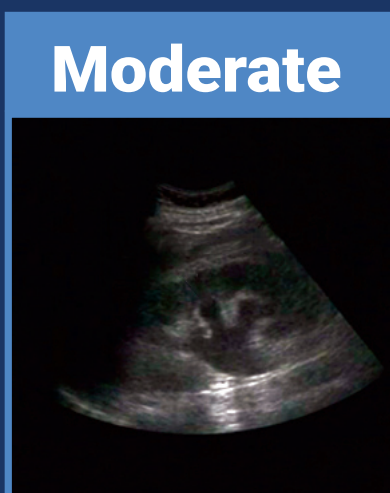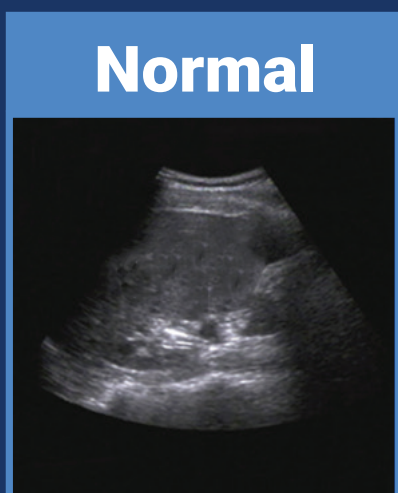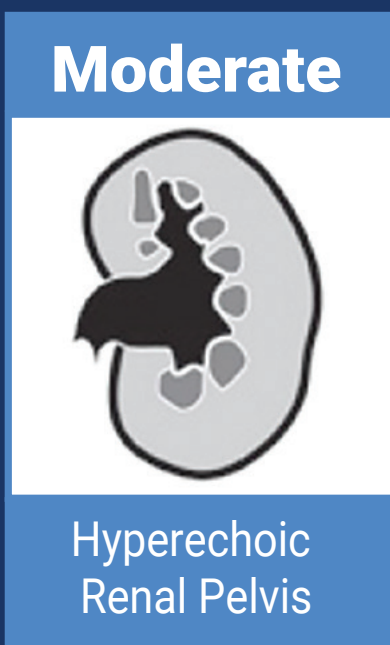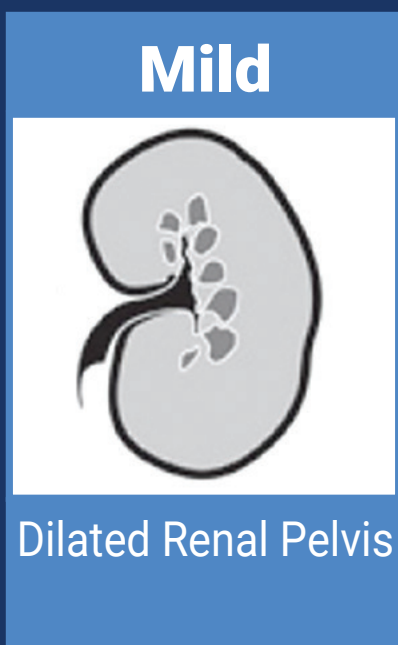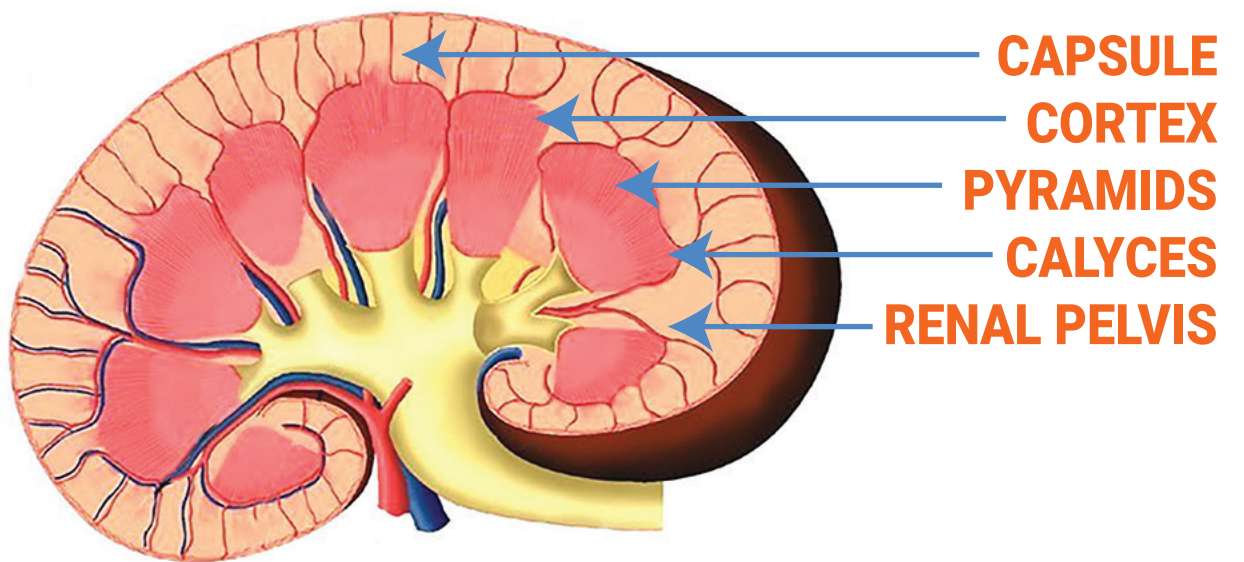


# Renal POCUS

## Look For Evidence Of Hydronephrosis!

**NORMAL ANATOMY** →  
 The Renal Pelvis is hyperechoic on ultrasound.



↑  
**Hydronephrosis**