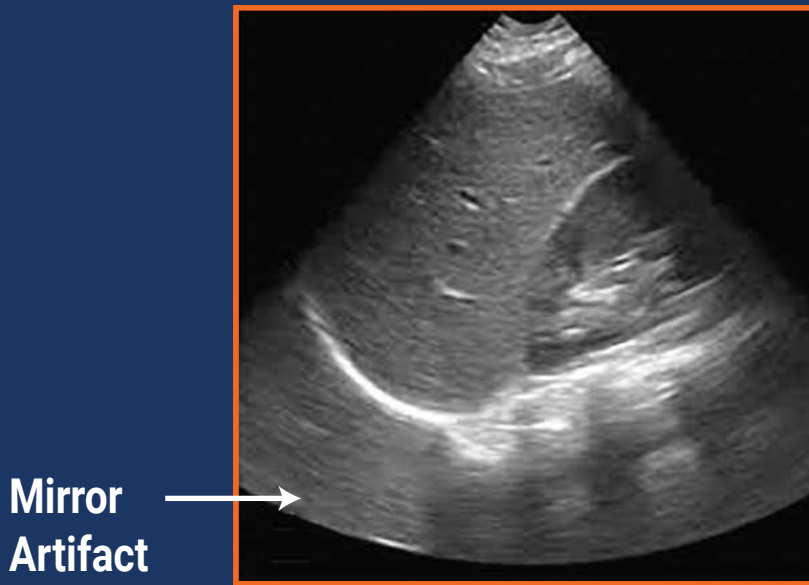
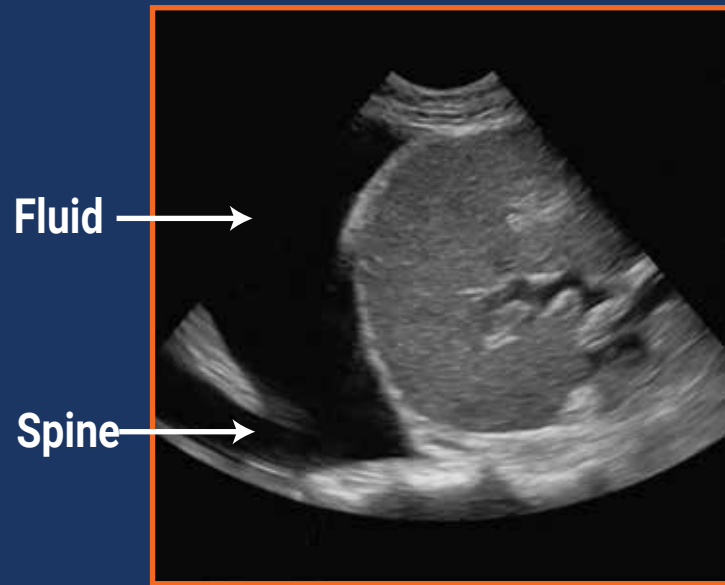


Pneumonia

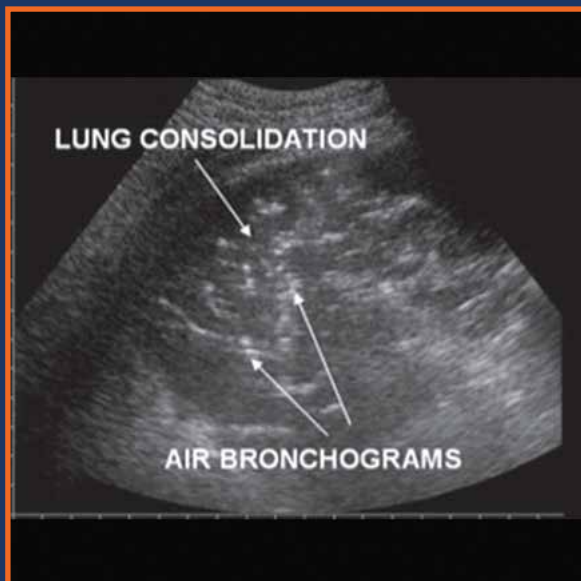
Normal



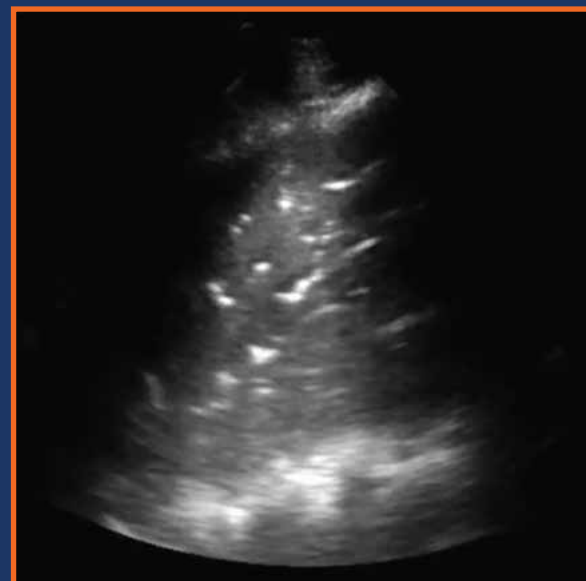**- Pleural Effusion
- Spine Sign**



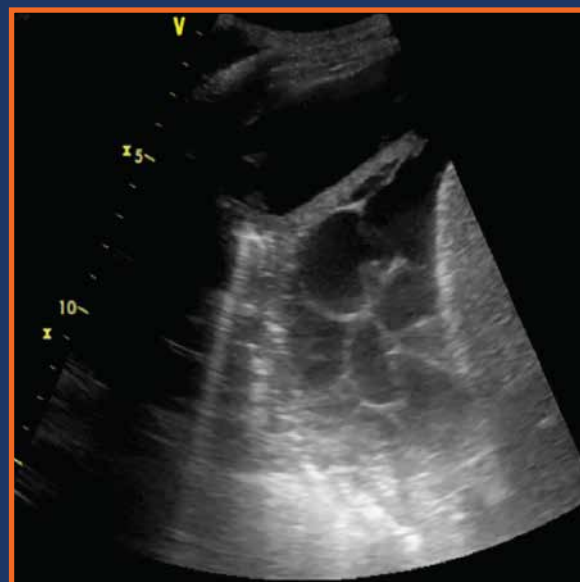
**Air Bronchogram
Note: Hyperechoic Alveoli**



**Dynamic Air Bronchogram
Note: On video, Echogenic
air will move
with respiration**



**Complex
Loculated
Effusion**



- With or without septations
- Exudative

