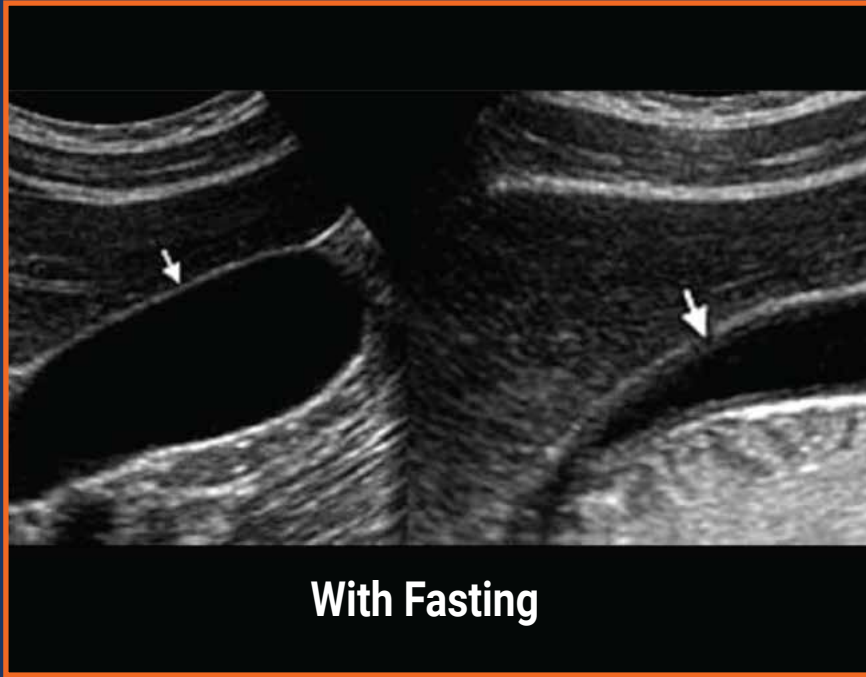
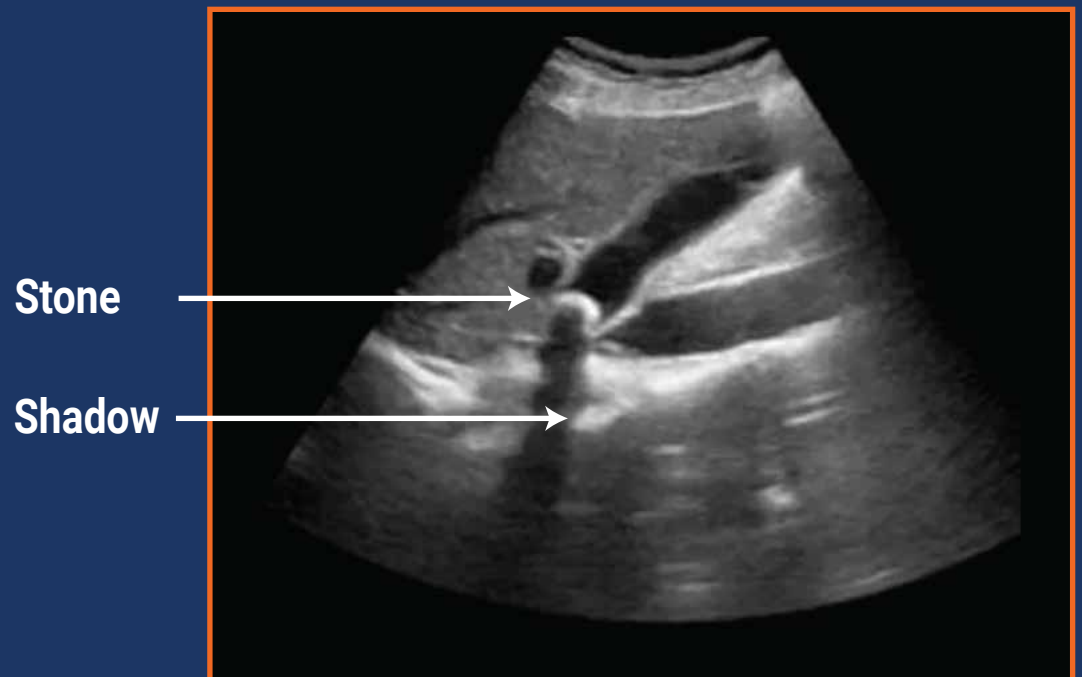


# Gall Bladder

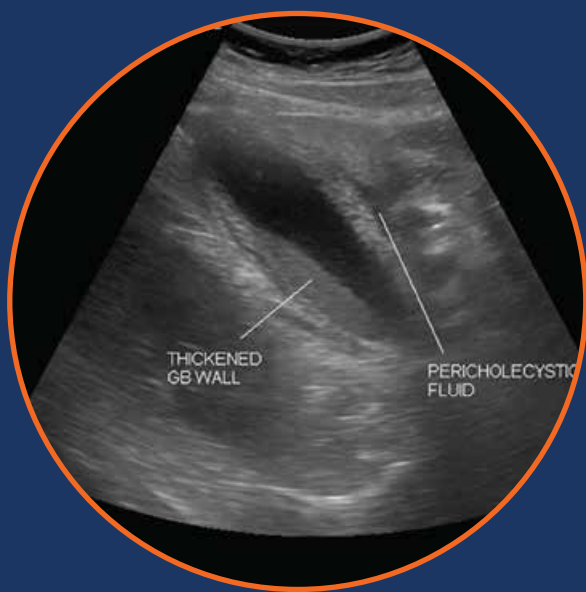**GB Distension**



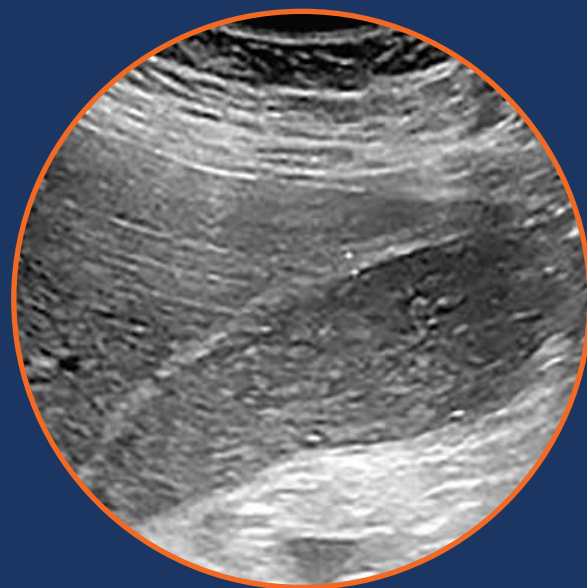
**SIN Sign  
(Stuck in Neck)**



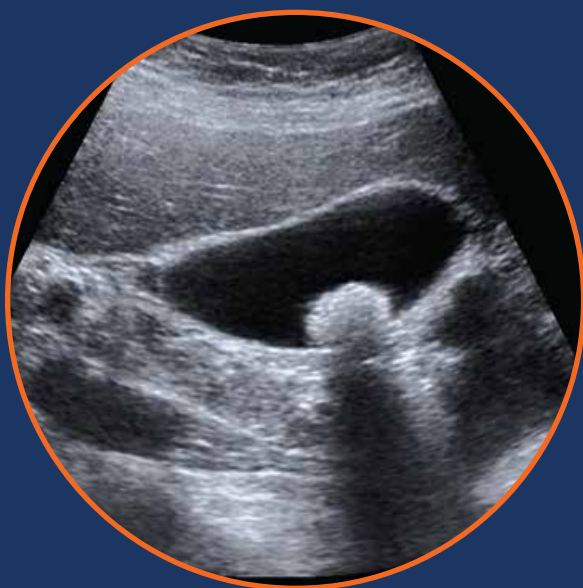**Thick Wall  
Pericholecystic Fluid**



**Sludge**



**Large Gallstone**



**Multiple Stones**

