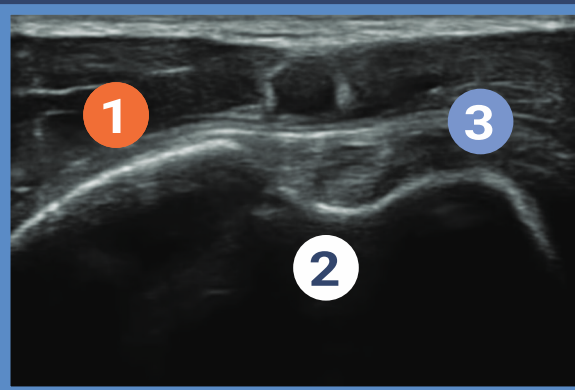
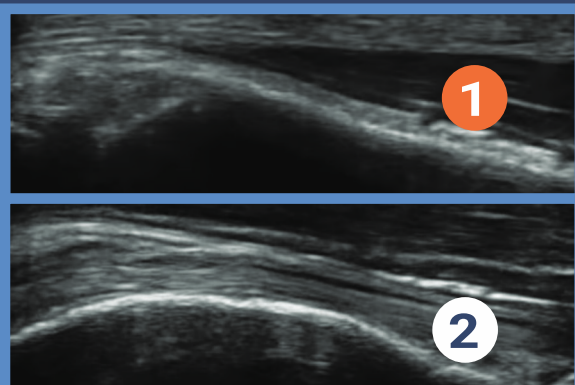
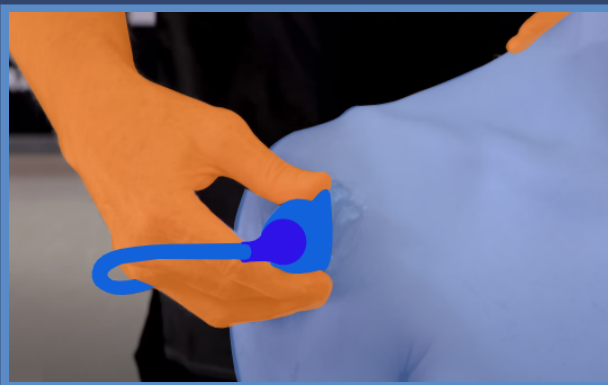


Shoulder MSK



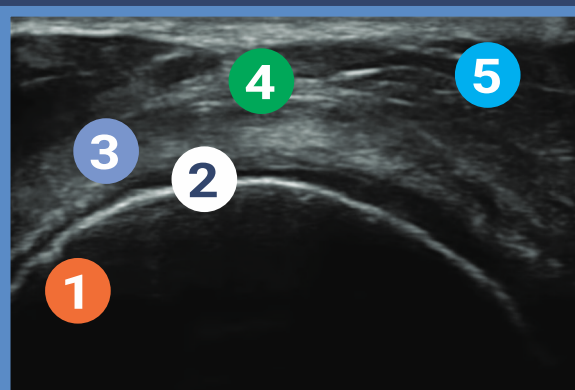
SAX View of Biceps Tendon

- 1 LONG Convexity of the greater tuberosity
- 2 Dip of Bicipital Groove
- 3 Lesser tuberosity of the humerus



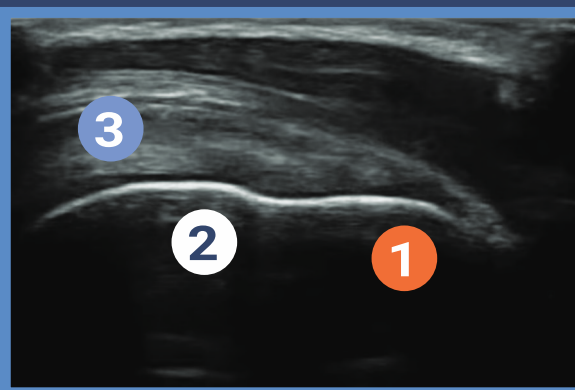
LONG view of Biceps tendon spin

- 1 Elongate the cordial margin of the humerus
- 2 Slide transducer and now Bicep tendon fibers come into view



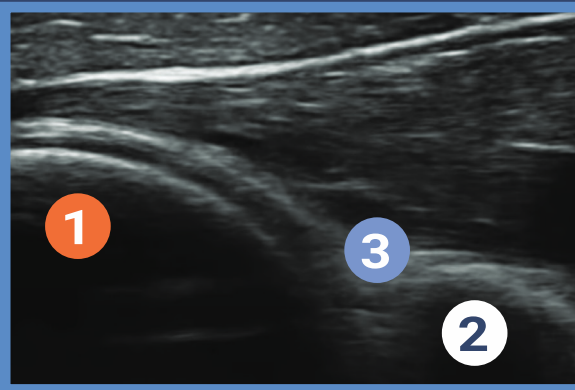
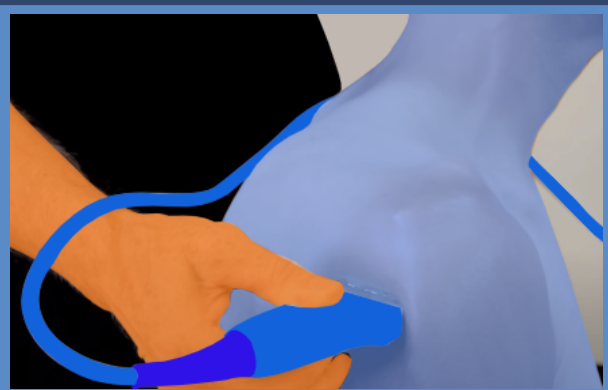
SAX view of the supraspinatus tendon

- 1 ID the Broad complexity of the humeral head
- 2 ID the black anechoic layer of the Hyoid cartilage
- 3 The supraspinatus tendon wraps around the margin of the humeral convexity
- 4 ID sub deltoid bursa
- 5 The deltoid muscle is superficial to the deltoid bursa



LONG view of the tendon attachment of the greater tuberosity of the humerus

- 1 Note the Flat slope of the greater tuberosity
- 2 Convexity of the humoral head
- 3 Note the supraspinatus tendon tapers to a sharp point (AKA the Bird's beak view)



SAX view of the posterior glenohumeral joint

- 1 ID the round convexity of the humeral head
- 2 Note the sharp point of the apex of the glenoid
- 3 Note the Posterior margin of the glenoid labrum (ligament)



POCUS™
Point-of-Care Ultrasound
Certification Academy

The Point-of-Care Ultrasound (POCUS) Certification Academy™ exists to provide physicians and advanced care providers the opportunity to collaborate in the shared mission of improving global health and setting the standards of excellence in POCUS.