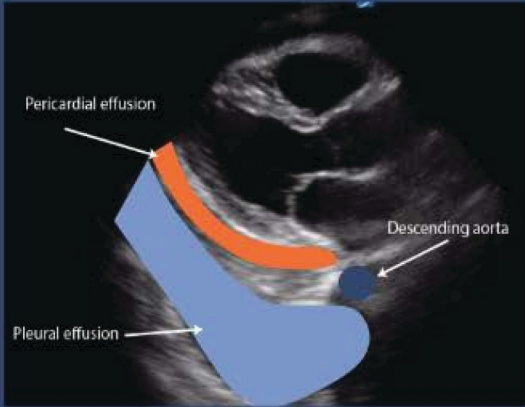


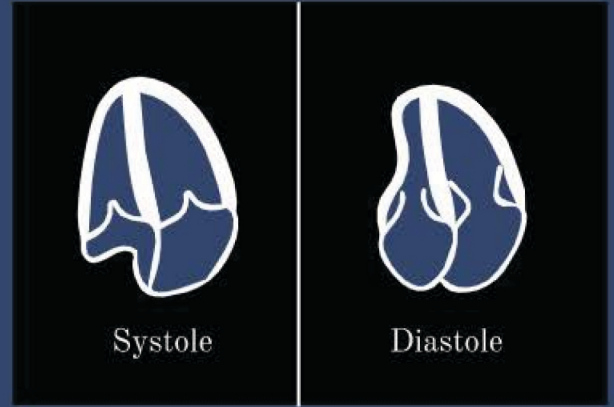
PERICARDIAL EFFUSION

Pleural vs Pericardial?



In Plax View: Is fluid above or below descending aorta?

Right Sided Collapse?



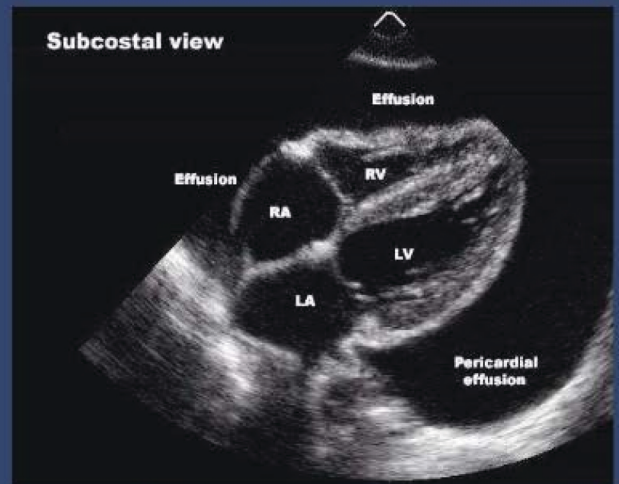
RA Collapse- Valves are closed
RV Collapse- Valves are open

Classification?

Onset	Acute Subacute Chronic (>3 months)
Size	Mild < 10 mm Moderate 10-20 mm Large > 20 mm
Distribution	Circumferential Loculated
Composition	Transudate Exudate

NL Fluid is 30-50ml of thin clear straw colored fluid.

Approaching Tamponade?



Large Effusions- take time and pericardium accommodates
Moderate Effusions- take days or hours, pericardium hasn't adapted