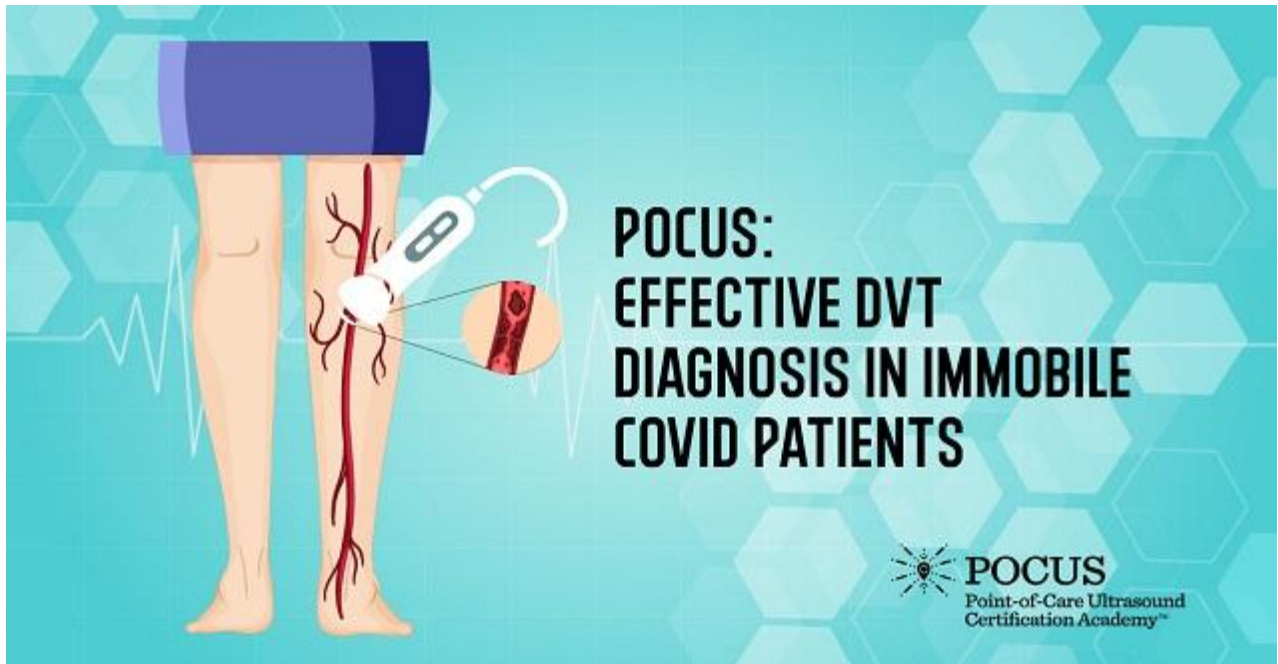




POCUS Post

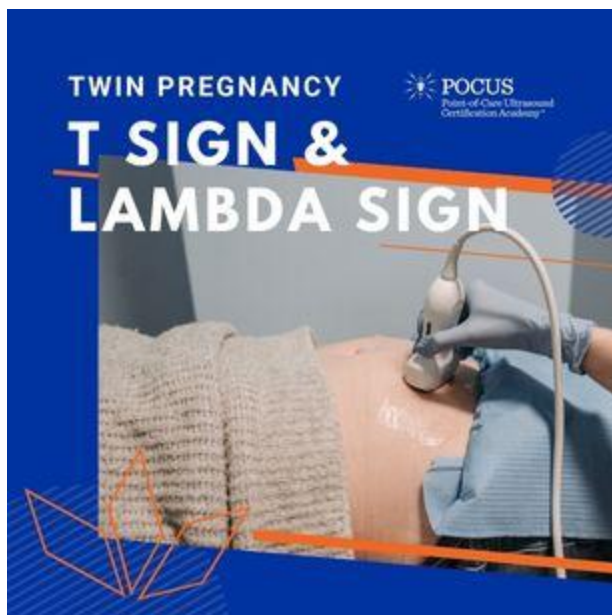March 23, 2022



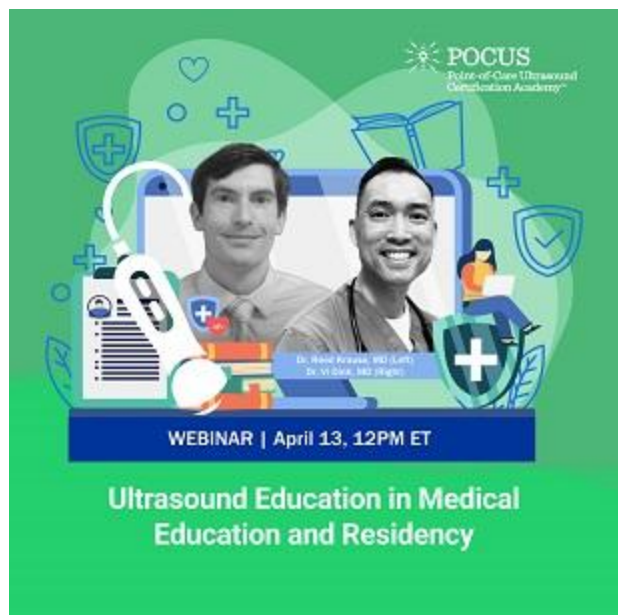
POCUS: Effective DVT Diagnosis in Immobile COVID Patients

"Nurse Jane D. began her morning shift in the ICU like many other days. Her first stop on her morning rounds was Bob, a patient recently admitted to the ICU due to COVID-19. Bob was conscious but on a ventilator to augment his breathing. As Jane assessed Bob, she noted that his left leg was red, swollen, and hot to the touch. Bob communicated that his leg was in a great deal of pain. After speaking with Dr. Ready, a point-of-care ultrasound (POCUS) order was placed for Bob's leg."

Keep Reading



Learn how to determine biparietal diameter and head circumference via point-of-care ultrasound scan.

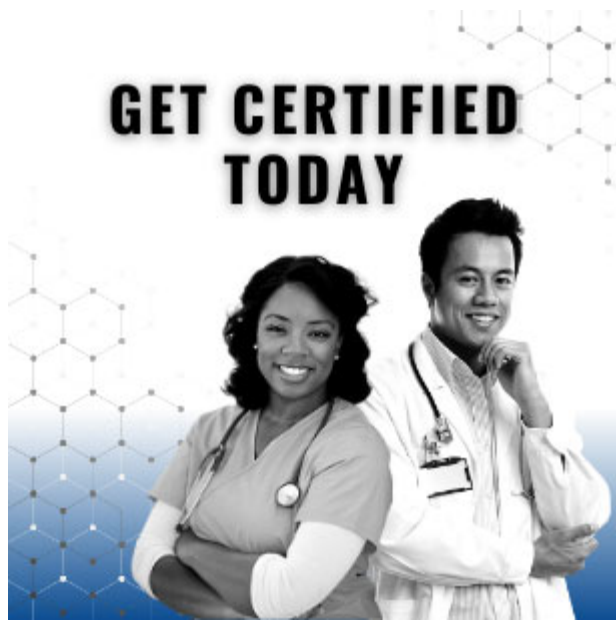

Learn how to integrate POCUS into longitudinal programs, overcome barriers, and access tools in this free webinar!

[Watch the Video](#)

[Register Here](#)





POCUS Lower Extremity Deep Vein Thrombosis Certificate

This certification consists of online cases to assess your knowledge in identifying anatomical features, views, sonographic and diagnostic findings, and potential diagnoses including:

- Baker's Cyst
- Deep femoral DVT
- Great saphenous vein thrombosis
- Popliteal DVT

[Learn More](#)

“ Just seeing the utility of (POCUS) can increase people using it, and as more people are using it... we can greatly increase access to POCUS.”
 - Brandon Greer, NP

Brandon Greer, NP, shares his experiences in increasing global access to point-of-care ultrasound.

POCUS Point-of-Care Ultrasound Certification Academy™

B-mode M-mode

Color Doppler Power Doppler Spectral Doppler

Knobology

Click the button below to view the full infographic on our website! PDF versions are available to download.

[Listen Here](#)

[View Infographic](#)

POCUS@inteleos.org | POCUS.org

Copyright © 2020 Alliance for Physician Certification & Advancement. All rights reserved.

[Please click here to manage your email preferences or unsubscribe.](#)

1401 Rockville Pike, Suite 600, Rockville, MD 20852