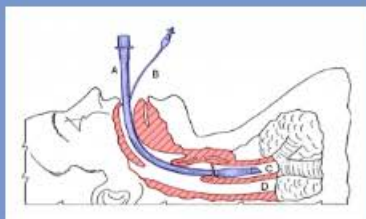


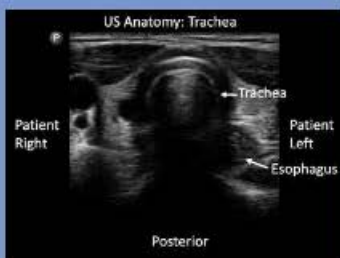
CONFIRM ENDOTRACHEAL TUBE PLACEMENT



A= Trachea
B= Esophagus



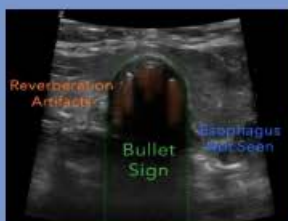Place linear probe
just above sternal
notch



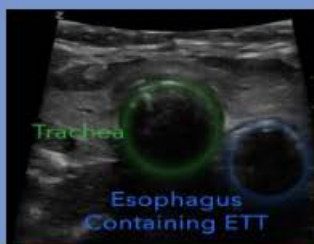US Anatomy Trachea

GOOD

BAD



Reverberations in the
trachea's anterior lumen
Mildly shake the ETT:
should only show
trachea movement



"Double Tract Sign"
Esophageal intubation
causes a 2nd 'trachea'
to appear



POCUS™
Point-of-Care Ultrasound
Certification Academy

The Point-of-Care Ultrasound (POCUS) Certification Academy™ exists to provide physicians and advanced care providers the opportunity to collaborate in the shared mission of improving global health and setting the standards of excellence in POCUS.
Pocus.org/Tips